

A free muscle flap monitored with Microdialysis.

Hanne Birke Sørensen, MD, Consultant, Department of Plastic Surgery, Århus University Hospital, Denmark

Introduction

Microdialysis has been the method of choice for monitoring free flaps in Århus University Hospital since September 1998. In the beginning the free flaps were monitored with microdialysis and clinical observation. From the beginning of 2000 microdialysis has been the routine method of monitoring, and based on clinical experiences, it has been possible during this period to identify normal as well as critical values for the different sorts of free flaps.

Case story

A 71-year-old man with an open fracture of the right tibia was referred to the Plastic Surgery department in March 2004 for soft tissue covering of the fracture. At the time of operation the fracture was 5 weeks old, but unstable despite external fixation. The patient was diabetic and suffered from arterial hypertension.

Operation

The operation was performed with the patient in general anaesthesia combined with epidural analgesia. At the right leg the wound and the fracture was revised and stabilized. The posterior tibial artery and vein were dissected free proximal to the fracture. At the abdomen the left rectus abdominis muscle was prepared as a free flap based on the inferior epigastric vessels. The muscle was taken to the leg and the anastomoses were performed end-to-end using Ackland clamps and interrupted sutures. After removing the clamps there was no pulse distally in the flap, but bleeding was observed in the peripheral part of the flap, and the situation seemed acceptable. The muscle was folded on itself and could easily cover the fracture as well as the

vessels. Split skin grafts were harvested at the right femur for later use.

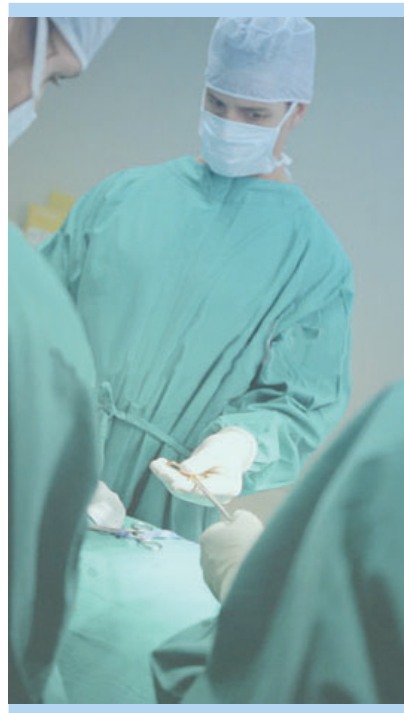Microdialysis

A Microdialysis Catheter (CMA 60) was placed in the medial part of the flap passing through the adjacent skin. Before the patient left the operating room an analysis was made of the first dialysates which showed normal values.

Postoperative observation plan

The Surgeons were confident with using Microdialysis as the only monitoring tool, therefore the free flap was covered up with no plans for an inspection of the flap until the following day when they were to put on the split skin.

Analysis of microdialysates was made every 30 minutes for the next 24 hours.



Re-operation decided

During the first four hours postoperatively the microdialysis values changed pathologically; glucose decreased rapidly and lactate increased to more than 20 mM, fig. 1 (see other side). The patient was stable with respect to pulse and blood pressure. The muscle flap was covered up and the leg was elevated. Based on the Microdialysis data the decision was made to re-operate.

Re-operation

In the operating room the leg was unwrapped. The free muscle flap clinically looked satisfactory without any signs of ischemia or venous obstruction. There was still bleeding from the peripheral part. The vessels were inspected thoroughly and no flow was seen in the posterior tibial artery, meaning that bleeding from the flap had to be based on venous inflow from the posterior tibial vein with insufficient valves. The artery was dissected 5 centimeters further proximally and a new anastomosis was performed. Immediately there was good perfusion of the free flap and a pulse in the very distal part of the flap. A new vein anastomosis was performed since the flap had to be placed further proximally. Before leaving the operating room glucose and lactate values were thoroughly improving fig. 2 (see other side).

After Surgery

The next day the split skin was put on the muscle and it healed well except for 5 % where a new split skin graft was put on a couple of weeks later.



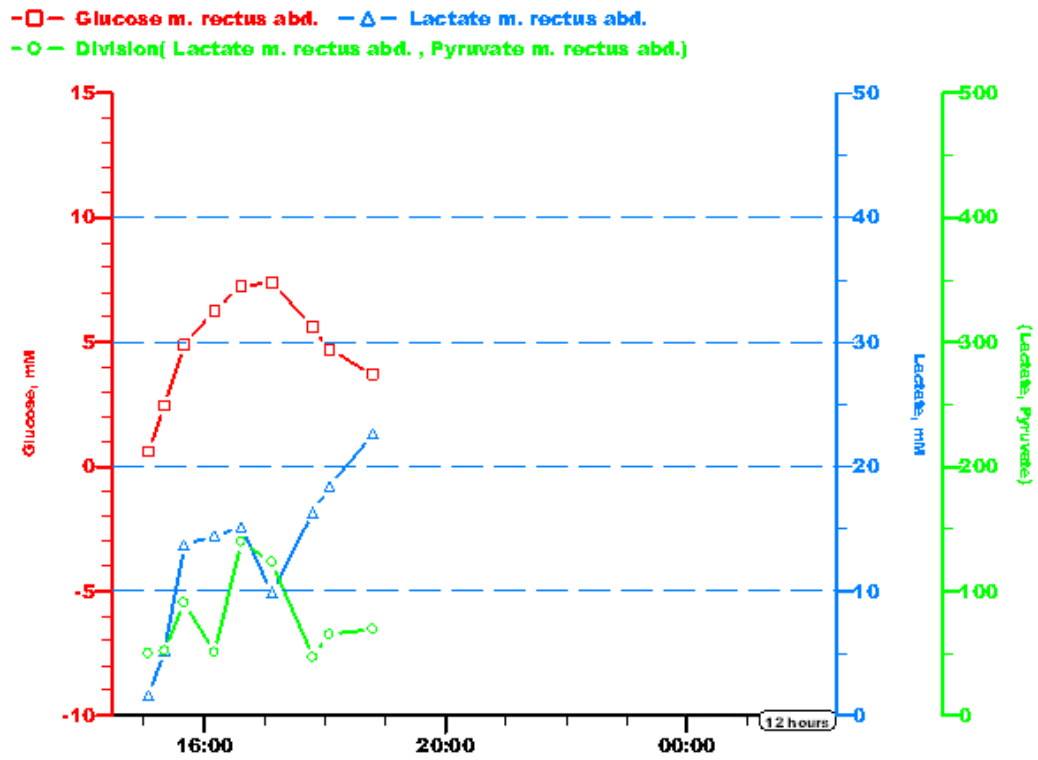


fig. 1

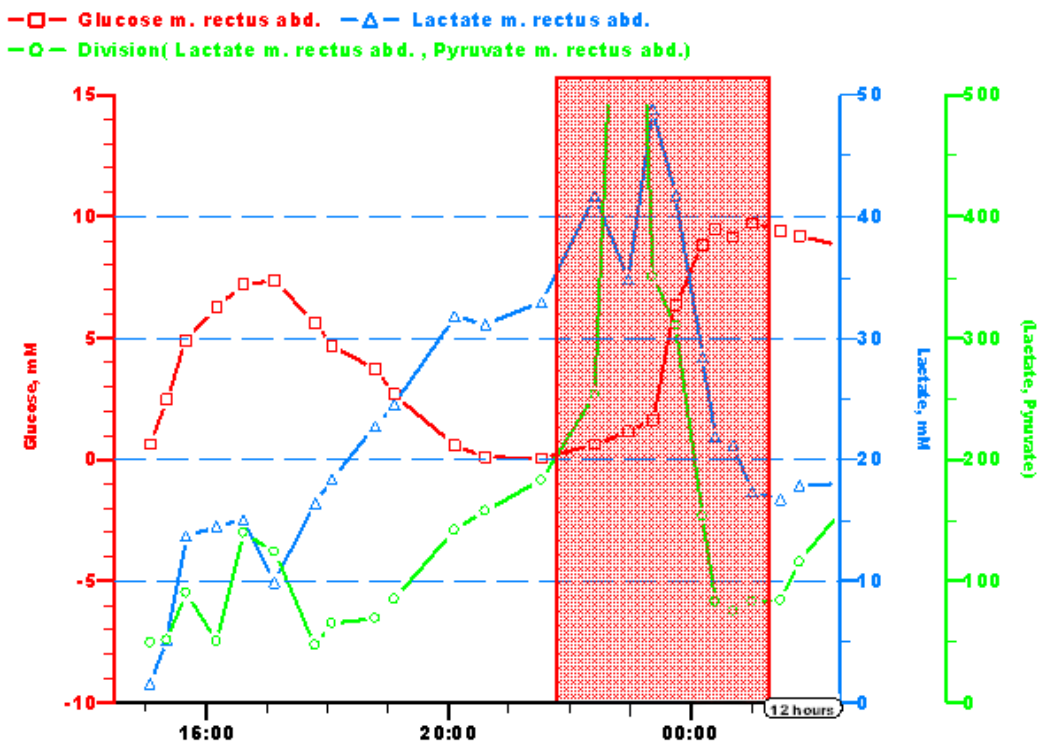


fig. 2